



**PRESENTING CLINICAL SIGNS**

**DATE** History: Low-grade heart murmur. Had a recent seizure-like episode.

**ECHOCARDIOGRAPHIC FINDINGS**

2/7/22 2D, M-mode, and Doppler study.

**PERFORMED BY:** Left atrial size is normal. The mitral valve is normal. Left ventricular dimensions are normal. Left ventricular systolic function is mildly hyperdynamic. The aorta and aortic valve are normal. Right atrial and right ventricular dimensions are normal. The tricuspid valve appears normal, though trace tricuspid regurgitation is present. The pulmonary artery and pulmonic valve are normal. No pericardial effusion or cardiac masses are seen.

Dr. Meredith Swart

**INTERPRETED BY**

Keith Blass, DVM,  
MS, DACVIM  
(Cardiology)  
LA - 21.8 mm  
LVIDd - 17.0 mm  
LVIDs - 9.4 mm  
FS - 44.7%  
LVOT - 0.67 m/s  
RVOT - 0.92 m/s

**PATIENT**

Stubby Tomlin **ASSESSMENT/RECOMMENDATIONS**  
Normal echocardiogram

**SPECIES** This examination demonstrates no evidence of structural heart disease, as trace tricuspid regurgitation can be considered a normal physiologic variant. As such, no reason for Stubby's seizure-like episode is appreciated in the image set. If syncope, rather than seizure, occurred, consideration should be given to an intermittent arrhythmia and vasovagal syncope as possible causes.

Canine

**BREED** No therapy is recommended based on this exam.

Pekingese Mix A recheck echocardiogram is recommended if the characteristics of Stubby's murmur change, or if other new physical exam and/or clinical abnormalities suggestive of cardiac dysfunction develop.

**SEX**

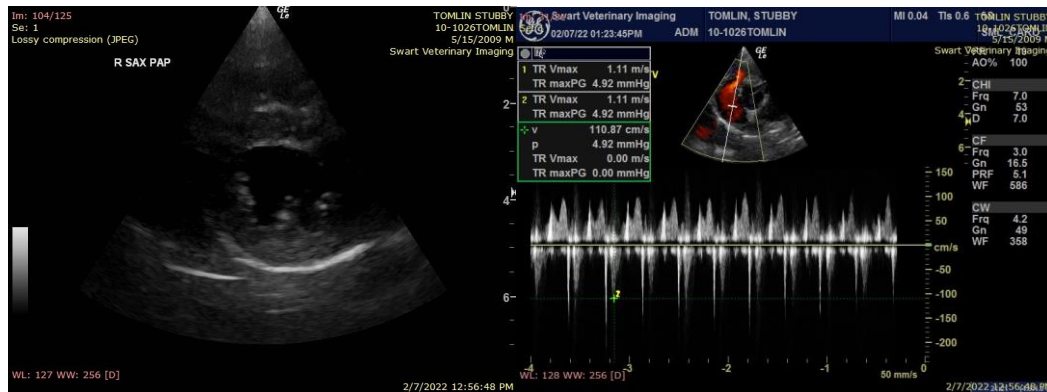
MN

**AGE**

12 y

**WEIGHT**

12 lb



**HOSPITAL NAME** The information and recommendations provided are based on the images presented by the referring veterinarian. No evaluation can be communicated regarding pathology that was not visible in the image/video clips provided.

Swart Veterinary Imaging Thank you for this referral. If the clinical or image interpretation does not parallel your findings or if I can be of any further assistance please contact me.

**REFERRING VET**

Dr. Swart



**Keith Blass, DVM, MS, DACVIM (Cardiology)**

**DATE**  
KeithBlass@gmail.com  
631-804-5754

2/7/22

**PERFORMED BY:**

Dr. Meredith Swart

**INTERPRETED BY**

Keith Blass, DVM,  
MS, DACVIM  
(Cardiology)

**PATIENT**

Stubby Tomlin

**SPECIES**

Canine

**BREED**

Pekingese Mix

**SEX**

MN

**AGE**

12 y

**WEIGHT**

12 lb

**HOSPITAL NAME**

Swart Veterinary  
Imaging

**REFERRING VET**

Dr. Swart